

# Quality of life results after vitreolysis in patients with symptomatic vitreous floaters

Renzo Cañote, Daniela Rodríguez, Luis Izquierdo Jr, Roger Moncada, Carmen Maldonado, Maria Alejandra Henríquez

Research Department, Oftalmosalud Eye Institute, Lima, Peru

## Abstract

**Purpose:** The purpose of the study was to evaluate the quality of life and visual results after yttrium aluminum garnet (YAG) vitreolysis in symptomatic vitreous floaters.

**Methods:** This was a prospective case series study including patients with symptomatic floaters attending the Oftalmosalud Institute of eyes and underwent YAG laser vitreolysis. All patients completed the National Eye Institute Visual Functioning Questionnaire 25 for the quality of life assessment and the presence of floaters as well as the measure of the visual acuity reported preprocedure and after 3-month follow-up. Statistical analysis was done using score 0–100 for each question, and a sign test for paired samples was used.

**Results:** Twenty eyes of 20 patients were evaluated. The comparisons for the questionnaire show an improvement in the general vision ( $P = 0.008$ ), near vision ( $P = 0.001$ ), and distance vision ( $P = 0.012$ ). Furthermore, the dependency of glasses ( $P = 0.012$ ), the score of mental health ( $P = 0.007$ ), and the best visual acuity ( $P = 0.004$ ) were improved. Patients who referred improvement in the quality of life were 75% pseudophakic patients and 25% phakic patients. The complications were high intraocular pressure and subcapsular cataract.

**Conclusions:** Our study revealed a moderate improvement in floater symptoms and in quality of life and visual outcomes.

**Keywords:** National Eye Institute Visual Functioning Questionnaire-25, quality of life, vitreous floaters, yttrium aluminum garnet vitreolysis

**Address for correspondence:** Dr. Daniela Rodríguez, Oftalmosalud Institute of Eyes, Av. Javier Prado Este 1142, San Isidro, Lima 27, Peru.  
E-mail: [danielarodriguezmesias@gmail.com](mailto:danielarodriguezmesias@gmail.com)

**Received:** 21 November 2019, **Accepted:** 16 December 2019, **Published Online:** 23 January 2020

## INTRODUCTION

The vitreous is a hydrated extracellular matrix comprised primarily with water, collagens, and hyaluronan, organized into a homogeneously transparent gel that helps to maintain the shape of the eye and achieve a uniform surface of the retina.<sup>[1,2]</sup>

During the first year of life, the vitreous gel is transparent, which allows an excellent refraction of the light, but with aging, molecular alterations take place as the dissociation of the collagen and the hyaluronic acid produces a liquefaction of the gel and the organization of collagen fibrils that leads to symptomatic floaters causing light scattering and entoptic phenomena to the patient, ultimately resulting in

This is an open access journal, and articles are distributed under the terms of the Creative Commons Attribution-NonCommercial-ShareAlike 4.0 License, which allows others to remix, tweak, and build upon the work non-commercially, as long as appropriate credit is given and the new creations are licensed under the identical terms.

**For reprints contact:** [reprints@medknow.com](mailto:reprints@medknow.com)

**How to cite this article:** Cañote R, Rodríguez D, Izquierdo L, Moncada R, Maldonado C, Henríquez MA. Quality of life results after vitreolysis in patients with symptomatic vitreous floaters. *Pan Am J Ophthalmol* 2020;2:2.

Access this article online	
Quick Response Code:	Website: <a href="http://www.thepajo.org">www.thepajo.org</a>
	DOI: 10.4103/PAJO.PAJO_24_19

posterior vitreous detachment (PVD)<sup>[3]</sup> which is present in the 60% of the population older than 60 years.

The treatments for this pathology are observation, vitrectomy, and yttrium aluminum garnet (YAG) vitreolysis; from this option, the vitrectomy presents complications such as secondary cataract, hypertension, and retinal breaks; on the other hand, the YAG vitreolysis has a revolutionary prism lighting system which is a split prism tower that produces semi-coaxial illumination, which illuminates deeper inside the vitreous and does not obstruct the laser beam allowing the clinician to see better and treat floats and opacities, making the treatment more controllable, accurate, and convenient.

Most of the patients tolerate their symptoms without problems; however, some patients find the floaters very problematic because it can reduce sensitivity to contrast and to quality of life<sup>[4]</sup> and also generate discomfort in daily activities. The visual quality and quality of life are measured with the National Eye Institute Visual Function Questionnaire (NEI VFQ) originally developed for patients with age-related macular degeneration, cataracts, diabetic neuropathy, and glaucoma and used in other ocular pathologies.<sup>[5]</sup>

The aim of this study was to evaluate the quality of life after YAG vitreolysis in patients with symptomatic vitreous floaters.

## METHODS

This was a prospective and descriptive case series study performed between June 2017 and November 2017 and included 20 eyes of 20 patients, at Oftalmosalud Instituto de Ojos, Lima, Peru. The study complied with the Declaration of Helsinki; the ethics committee of Oftalmosalud approved the study and written informed consent was obtained from all the participants.

The inclusion criteria were as follows: all patients who attended the clinic due to flashes of color, to a perception of floating flies or persistent mobile hairs secondary to PVD, and to the persistence of floating symptoms of at least 1 month, documented in the clinical examination. The diagnosis of PVD was confirmed by the retina specialist through a fundus examination and by B-ultrasound; it confirmed the presence of vitreous condensations, vitreous posterior detachment, and the presence of Weiss ring. Only one eye per participant was included in the study.

Patients with vitreous floaters secondary to vitreous hemorrhages, to vitreous retina surgeries, to asteroid

hyalosis, to scintillating sinquiasis, to inflammatory processes, other severe ocular diseases, and to postoperative retinal detachment by vitrectomy were excluded from the study.

All patients were examined by indirect ophthalmoscopy done by a retinal specialist who projected a light into the eye, using Keeler's Vantage plus indirect ophthalmoscope and Volk 2.2 pan retinal magnifying glass to visualize the fundus; also, patients underwent ultrasound test to confirm the diagnosis.

The best-corrected visual acuity and intraoperative and postoperative complications were recorded.

## National Eye Institute Visual Function Questionnaire-25

The NEI VFQ-25 (<https://www.nei.nih.gov/faqs/resources-visual-function-questionnaire-25-vfq-25>) was completed by each patient before the operation and 3 months after the procedure. This questionnaire is an instrument that allows assessing the quality of life related to vision. It consists of 1 general health item and 25 items grouped into 11 subscales [Table 1]: general vision (1 question), ocular pain (2 questions), near activities (3 questions), distance activities (3 questions), social functioning (2 questions), mental health (4 questions), role limitations (2 questions), dependency (3 questions), driving (3 questions), color vision (1 question), and peripheral vision (1 question). This questionnaire helped us to evaluate the subjective satisfaction that patients felt before and after the procedure (3 months postsurgery) in multiple aspects of everyday life. Furthermore, we added the following question to evaluate the reduction of visual discomfort after the treatment: Did the visual discomfort improved after the treatment? with a yes or no answer. A total of 26 questions were answered.

All the answers in every question were scored between 0 and 100 points, where 0 is the lowest and 100 is the best

**Table 1: National Eye Institute Visual Functioning Questionnaire-25 Questions according to the 11 scales**

Subscale	NEI VFQ-25 number of question included
General vision	2
Near vision	5, 6, 7
Distance vision	8, 9, 14
Driving	15c, 16, 16a
Peripheral vision	10
Color vision	12
Ocular pain	4, 19
Role limitations	17, 18
Dependency	20, 23, 24
Social function	11, 13
Mental health	3, 21, 22, 25

A total of 25 questions were separated according the 11 subscales.

NEI VFQ: National Eye Institute Visual Functioning Questionnaire 25

possible score, and the questions were separated in the 11 scales and the vision-related subscale scores were averaged without the general health question.<sup>[5,6]</sup>

### Vitreolysis procedure

The patient's pupil was dilated with tetracaine hydrochloride (5.0 mg), 1 drop every 5 min for 15 min; it was recommended for patients to keep their eyes closed, after confirming the eyes dilatation. One drop of anesthetic (tropicamide) was applied, and one drop of gel carbomer was instilled into the lens that was used to perform the process (Ocular Peyman 18 mm Vit. Lens, Karickhoff 21 mm Vitreous Eyepiece, and Karickhoff Eyepiece 25 mm Vit. Off Axis). The patient was asked to fix the gaze at a fixed point.

YAG vitreolysis was performed with LIGHTLas YAG/selective laser trabeculoplasty Deux (Lightmed, San Clemente, California, United States). A maximum energy per pulse of 7 mJ was used, as described by Tsai *et al.*<sup>[7-9]</sup> The energy was initially shown at 2.5 mJ. It is recommended to start the treatment with a simple pulse per shot. The energy was set to the minimum level required to create the interruption in the vitreous cavity (usually 2.5 mJ). Most treatments can be performed using energy between 2.5 mJ and 4–5 mJ. It is possible to increase to two pulses (double) or three pulses (triple) per shot before increasing the energy per shot. It is recommended to limit the number of shots to a maximum of 450–500 per vitreolysis session. If more sessions are required, it can be done with a period of 1 month with a maximum of 500 shots per session. Additional sessions were considered if the patient reported that the perception of the flies did not disappear completely and had no complications.

The sessions were repeated until the patients reported that the improvement was complete and consent for a new procedure; the maximum session per patient was 4.

### Postoperative assessment

After treatment with YAG laser, no topical therapy was given postoperatively. All the patients were checked a week after to evaluate the perception of the vitreous floaters and for the follow-up of the intraocular pressure. If the patients reported total improvement, they were checked a month after the procedure. If the patients improved partially or no improvement, it was scheduled more visits with a space of 15 days apart until the vitreous floaters disappeared.

### Statistical analysis

Statistical analysis was performed using the R program version 3.6.0 from the R foundation, Vienna, Austria. (<https://www.r-project.org/>). The 25 questions (without

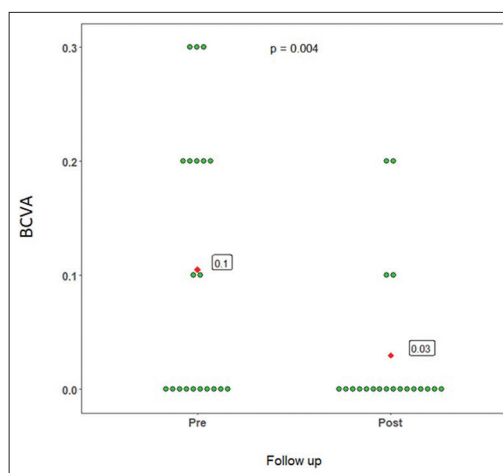
the question of general health) were scored 0–100 for each question (according to the number of options for each question, it was given a score 0–100).<sup>[6]</sup> The questions on each scale were averaged.

The data collected were summarized using the statistics: mean, standard deviation (SD), and range (minimum and maximum values). The sign test for paired samples was performed to compare the measurements before and after the ophthalmologic intervention. For all statistical tests, a type I error equal to 0.05 was considered.

## RESULTS

Of twenty patients, 20 eyes were treated for symptomatic acute floaters; all were followed-up for 3 months. The mean  $\pm$  SD age of participants was  $59.4 \pm 7.6$  years. The mean best-corrected visual acuity before and after the procedure was  $0.11 \pm 0.12$  and  $0.3 \pm 0.6$ , respectively, with a significant improvement ( $P = 0.002$ ) [Figure 1]. Table 2 shows the characteristics pre procedure and the complications post follow-up.

Most of the patients received only laser treatment (60%, 12/20) with a mean total power of  $3.33 \pm 0.82$  mJ and  $333.92 \pm 90.07$  shots. About 15% (3/20) of the patients received two sessions with a mean total power of



**Figure 1:** Best-corrected visual acuity results pre- and postprocedure

**Table 2:** Characteristics preoperative of patients

	n (%)
Eyes	
Right	12 (60)
Left	8 (40)
Phakic	9 (45)
Pseudophakic	11 (55)
Complications	
Cataract	1 (5)
Hypertension	3 (15)
No complications	16 (80)

3.33 ± 0.58 mJ with a mean of shots of 280 ± 103.92 in the first session and a mean total power of 3.33 ± 0.058 mJ with a mean of shots of 306 ± 38.11 in the second session. Furthermore, 15% (3/20) of the patients received three sessions with a mean total power and a mean shot in the first session of 3.3 ± 0.75 mJ and 413.33 ± 99.48 shots, in the second session, they were 3 ± 0.26 mJ and 320 ± 36.38 shots, and in the third session, they were 3.66 ± 1.15 mJ and 452.33 ± 91.36 shots. Only 10% (2/20) of the patients received four sessions with a mean total power and a mean of shots of 4.05 ± 1.48 mJ and 500 ± 0 shots in the first session, 3.5 ± 0.71 mJ and 500 ± 0 shots in the second session, 4 ± 0 mJ and 244 ± 69.29 shots in the third session, and 4 ± 0 mJ and 250 ± 0 shots in the fourth session. All the patients who underwent second, third, or four session reported a partial or no improvement. For the question 26, in general, 60% of the patients reported an improvement in the visual discomfort at the first session and 40% none or partial improvement. From the 60% (12/20) patients, 4 did not receive additional sessions due to a complication. From the 40% (8/20) of the patients received an additional session, 25% (5/20) reported partial improvement and 10% (3/20) did not improve despite having four laser sessions in total; this fourth session was the last one. The visual acuity improves from pretreatment to posttreatment ( $P = 0.004$ ) [Figure 1].

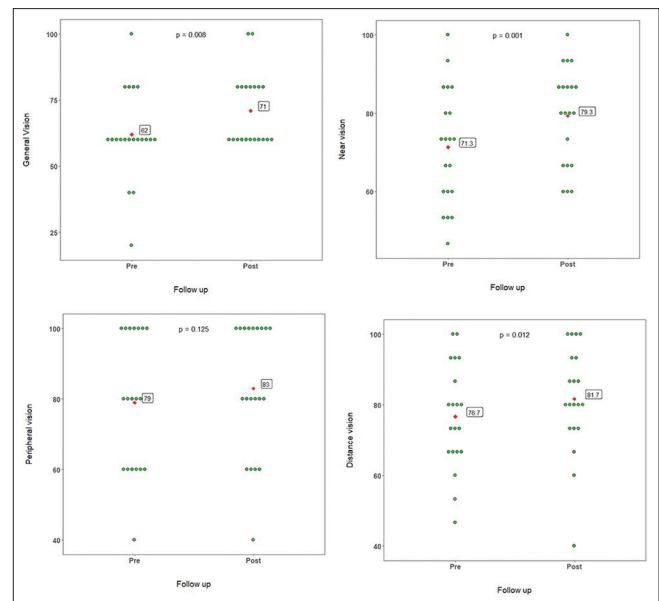
The quality of life was evaluated with the NEI VFQ-25, in which the questions were grouped into 11 scales and scored from 0 to 100; all questions in each scale were averaged and compared pre- and posttreatment values.

Figure 2 shows the results of the visual scales, where the general vision scale has an improvement ( $P = 0.008$ ), where the score was greater at the follow-up, and the near vision and distance vision have a higher score in the post procedure with a significant  $P$  value,  $P = 0.001$  and  $P = 0.012$ , respectively. The peripheral vision continues the same in the follow-up.

For the other scales [Figure 3], it was a significant improvement in the dependency scale ( $P = 0.012$ ) and in the mental health (0.007).

### Complications

During the vitreolysis procedure, 1 patient, with only one session with 300 shots and 3 mJ of power, had a rupture of the posterior capsule of the crystalline lens; after 3 days, it had a localized opacity of the crystalline lens, which led to a subcapsular cataract; due to this, a phacoemulsification surgery with an intraocular lens implant was performed.



**Figure 2:** Results of visual scales from National Eye Institute Visual Functioning Questionnaire-25. All scales were scored (0-100) and compared. The general vision, near vision, peripheral vision and distance vision had an improvement in the score after 3 months of follow up

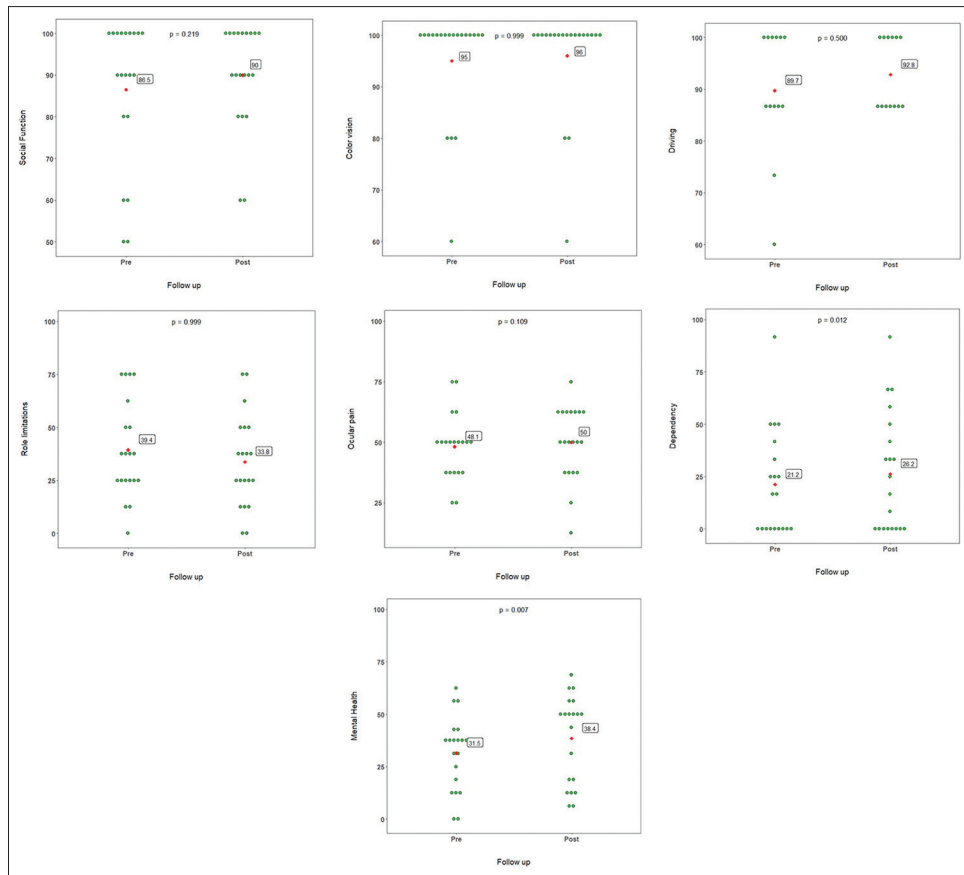
Transient ocular hypertension was present on 3 patients a week after the first session: two of them received 420 shots with 3 mJ and the third patient received 329 shots with 5 mJ. Hypertension was managed with antihypertensive drops, 1 drop twice a day (beta-blocker timolol). The intraocular pressure was monitored weekly if the patient presented a low pressure in the 2<sup>nd</sup> week the medication was withdrawn, and all patients were controlled for 4 more weeks.

The patients who did present hypertension had a mean laser shot of 389 ± 52.54 (3/20) in the unique session, comparing with the first session of patients with no hypertension 287.3 ± 125.62 (17/20), there was no significant difference ( $P = 0.27$ ).

### DISCUSSION

Vitreous floaters are a visual phenomenon caused by vitreous opacities which leads to produce linear gray shadows with focal dark spots or nodules.<sup>[1]</sup> These visual phenomena affect not only the vision of the patient but also the quality of life.

The use of neodymium (Nd)-YAG laser for the treatment of floaters was already described since 1987<sup>[8-10]</sup> in some studies; only a third part of the patients refers improvement in the symptoms after the procedure,<sup>[7]</sup> but these vary from one study to other. Furthermore, this treatment is noninvasive and considered by several authors as effective, safe, and innocuous<sup>[11,12]</sup> for the patients and could improve the quality of life.



**Figure 3:** Results from quality of life scale from National Eye Institute Visual Functioning Questionnaire-25. The scales were scored (0-100) and compare after 3 months of follow up. The dependency of glasses ( $P=0.012$ ) and mental health ( $P=0.007$ ) had the best improvement in the score after the procedure

In the present study, we evaluated the quality of life after using YAG vitreolysis in patients with symptomatic vitreous floaters.

The visual acuity of these patients improves after 3 months' postsurgery; also, there were 60% (12/20) of the patients with an improvement after the first session, and these results can be study in a larger sample, due to in some studies, the improvement varies from 0% to 100%.<sup>[1]</sup> These results could have this variation according to the type of floaters and the location.<sup>[13]</sup>

These findings appear to show similar efficacy than those reported in an analysis of 39 patients treated for PVD-related floaters by Delaney *et al.*<sup>[7]</sup> where they used a maximum pulse energy of 1.2 mJ with a mean power of 310.4 mJ per session and reported that 38% found Nd:YAG vitreolysis moderately improved their symptoms, while 61.5% found no improvement.

The NEI VFQ-25 is a questionnaire that assesses the influence of visual impairment in the daily activities, comfort, and mental health among other scales;<sup>[14]</sup> it

measures the patient perception to all these different scales and let us to assess the impact of different conditions and treatments in the patient's life.<sup>[15]</sup> Using this questionnaire, the questions were grouped into 11 scales and were scored from 0 to 100(included all 25 questions). In this study, we can observe an improvement in almost all scales related to the vision of the patient such as general vision, near vision, and distance vision. This confirms the results obtained in the visual acuity that let us know the patients had a better vision with the correction and less discomfort for the remain floaters.

Other important result in the assessment is the dependency on others due to vision and mental health symptoms due to vision scale where also it was improvement, reflecting the state of minds of the patients . Wagle AM *et al.*<sup>[16]</sup> reported the utility value of floaters, as expressed by patients. This indicates that floaters have a significant negative impact on the quality of life as compared to ocular as well as systemic diseases; they reported that these patients were willing to take an 11% risk of death and a 7% risk of blindness to get rid of symptoms related to floaters. This indicates the importance to treat symptomatic vitreous floaters.

The surgical complication was caused by the operator's learning curve when performing the treatment. All complications were managed clinically.

It had been reported due to the use of the Nd-YAG laser in the posterior segment between the endothelium corneal damage, cataract,<sup>[16]</sup> hemovitreous, and retinal breaks or retinal detachment.<sup>[17-20]</sup> In our series cases, complications included local opacification of the crystalline lens in 1 eye, and 3 patients had transitory intraocular hypertension after YAG vitreolysis treatment. There was no retinal tear or retinal detachment, which was checked by indirect ophthalmoscopy and ultrasonography.

To avoid the cataract complications, it is described as a safe distance between the target tissue and the neighboring tissues of 2–5 mm.<sup>[21]</sup> Due to their location, most often in the anterior vitreous or mid-vitreous, vitreous floaters can be treated with the Nd-YAG laser while keeping a safe distance from the lens and from the retina. Although the new YAG laser is safer to perform procedures, it depends on the operator, and due to that, it could occur complications such as those presented in the current study.

Transient hypertension can be attributed to the inflammation in relation to the number of shots administered in each session at higher doses, and this is associated with the size of the floater, small floaters will need fewer sessions, fewer numbers of shots to dissolve them, and larger floaters will need more sessions and more shots, as described by Chirag.<sup>[22]</sup>

The current study has several limitations, including its small sample size and short follow-up period. Longer follow-up is required to determine the long-term stability of results and the degree of adverse events associated with the procedure.

## CONCLUSIONS

The current study suggests that YAG vitreolysis improves the quality of life and visual outcomes in patients presenting visual disturbance secondary to clinically confirmed vitreous floaters, both subjectively symptoms, with a few adverse events in this series.

## Acknowledgment

The authors would like to thank Jose Chauca for the statistical support.

## Financial support and sponsorship

Nil.

## Conflicts of interest

There are no conflicts of interest.

## REFERENCES

1. Milston R, Madigan MC, Sebag J. Vitreous floaters: Etiology, diagnostics, and management. *Surv Ophthalmol* 2016;61:211-27.
2. De Nie KF, Crama N, Tilanus MA, Klevering BJ, Boon CJ. Pars plana vitrectomy for disturbing primary vitreous floaters: Clinical outcome and patient satisfaction. *Graefes Arch Clin Exp Ophthalmol* 2013;251:1373-82.
3. Schulz-Key S, Carlsson JO, Crafoord S. Longterm follow-up of pars plana vitrectomy for vitreous floaters: Complications, outcomes and patient satisfaction. *Acta Ophthalmol* 2011;89:159-65.
4. Mamou J, Wa CA, Yee KM, Silverman RH, Ketterling JA, Sadun AA, *et al.* Ultrasound-based quantification of vitreous floaters correlates with contrast sensitivity and quality of life. *Invest Ophthalmol Vis Sci* 2015;56:1611-7.
5. Petrillo J, Bressler NM, Lamoureux E, Ferreira A, Cano S. Development of a new Rasch-based scoring algorithm for the national eye institute visual functioning questionnaire to improve its interpretability. *Health Qual Life Outcomes* 2017;15:157.
6. Coleman AL. Development of the 25-item national eye institute. Visual function questionnaire. *Evid Based Eye Care* 2002;3:58-9.
7. Delaney YM, Oyinloye A, Benjamin L. Nd: Yag vitreolysis and pars plana vitrectomy: Surgical treatment for vitreous floaters. *Eye (Lond)* 2002;16:21-6.
8. Fankhauser F, Kwasniewska S, Van Der Zypen E. Vitreolysis with the q-switched laser. *Arch Ophthalmol* 1985;103:1166-71.
9. Tsai WF, Chen YC, Su CY. Treatment of vitreous floaters with neodymium yag laser. *Br J Ophthalmol* 1993;77:485-8.
10. Little HL, Jack RL. YAG laser surgery of the vitreous. *Graef Arch Clin Exp Ophthalmol* 1986;224:240-6.
11. Vogel A, Hentschel W, Holzfuss J, Lauterborn W. Cavitation bubble dynamics and acoustic transient generation in ocular surgery with pulsed neodymium: Yag lasers. *Ophthalmology* 1986;93:1259-69.
12. Little HL, Jack RL. Q-switched neodymium: Yag laser surgery of the vitreous. *Graefes Arch Clin Exp Ophthalmol* 1986;224:240-6.
13. Vandorselaer T, van de Velde F, Tassignon MJ. Eligibility criteria for nd-yag laser treatment of highly symptomatic vitreous floaters. *Bull Soc Belge Ophthalmol* 2001;280:15-9.
14. Mangione CM, Lee PP, Gutierrez PR, Spritzer K, Berry S, Hays RD, *et al.* Development of the 25-item national eye institute visual function questionnaire. *Arch Ophthalmol* 2001;119:1050-8.
15. Suñer IJ, Bressler NM, Varma R, Dolan CM, Ward J, Turpcu A. Responsiveness of the national eye institute visual function questionnaire-25 to visual acuity gains in patients with diabetic macular edema: Evidence from the ride and rise trials. *Retina* 2017;37:1126-33.
16. Brown GC, Benson WE. Treatment of diabetic traction retinal detachment with the pulsed neodymium-yag laser. *Am J Ophthalmol* 1985;99:258-62.
17. Turut P, Malthieu D, Bryselbout E, Bego B. Section of posterior vitreal strands with the yag laser. *Bull Soc Ophthalmol Fr* 1987;87:813, 816-8.
18. Tassignon MJ, Kreissig I, Stempels N, Brihaye M. Indication for Q-switched and mode-locked ND: YAG Laser in vitreoretinal pathology. *Eur J Ophthalmol* 1991;1:123-30.
19. Gao YB. Vitreolysis with nd: Yag laser. *Zhonghua Yan Ke Za Zhi* 1990;26:352-4.
20. Benhamou N, Glacet-Bernard A, Le Mer Y, Quentel G, Perrenoud F, Coscas G, *et al.* Retinal detachment following yag laser section of vitreous strands. Apropos Of 3 Cases. *J Fr Ophthalmol* 1998;21:495-500.
21. Sebag J. Floaters and the quality of life. *Am J Ophthalmol* 2011;152:3-40.
22. Shah CP, Heier JS. Yag laser vitreolysis vs sham yag vitreolysis for symptomatic vitreous floaters: A randomized clinical trial. *JAMA Ophthalmol* 2017;135:918-23.