

Case Report

Poppers' Maculopathy

Renzo Cañote Flores, Johana Rueda Rueda

Department of Retina and Vitreous, Instituto de Ojos Oftamosalud, Lima, Perú

Abstract

We report a case of visual alterations after the first use of *poppers* in a young male patient. A 32-year-old male patient with no past medical history presented with decreased central visual acuity and phosphenes in both eyes. He admitted the use of *poppers* a day before the symptoms began. Optical coherence tomography showed bilateral disruption of the ellipsoid zone. *Poppers'* use is increasing in young people and so is the possibility of visual and structural alterations that can persist over time as a result of macular toxicity.

Keywords: Amyl nitrite, macular toxicity, poppers, poppers' maculopathy

Address for correspondence: Dr. Johana Rueda Rueda, Department of Retina and Vitreous, Instituto de Ojos Oftamosalud, Lima, Perú.

E-mail: johanar@outlook.com

Received: 27 July 2019, **Accepted:** 28 August 2019, **Published Online:** 26 September 2019

INTRODUCTION

Poppers are a group of psychoactive drugs called alkyl nitrites, and the term is especially used to describe the inhalant drug amyl nitrite. At the beginning, this group of drugs were used around the 1860s to treat angina and cyanide poisoning because of its vasodilation properties. The term *poppers* appeared in the 1960s when the capsules of amyl nitrite were cracked or "popped" to release the chemical, and since then, it is common among gay population, and nowadays it is becoming popular among young people as a recreational drug that can increase sexual desire and cause euphoria and vasodilation, and it is the fourth common drug in the frequency of usage after marijuana, cocaine, and ecstasy.^[1,2]

We report a case of visual alterations after the first use of this drug in a young male patient.

CASE REPORT

A 32-year-old male patient presented with a sudden

reduction in central visual acuity associated to phosphenes in both eyes for 2 days [Figure 1]. There was no past medical history. Anterior segment and intraocular pressure were normal in both eyes. Best-corrected visual acuity was 20/20 in the right and left eyes. Funduscopic examination showed a mild disruption in macular retinal pigment epithelium in both eyes [Figure 2]. Even when the findings were mild and inconclusive at the first sight, the patient insisted on the presence of visual symptoms. A spectral domain-optical coherence tomography (OCT) revealed foveal disruption at the ellipsoid zone (EZ) [Figure 3]. Fluorescein angiography showed no defects in the right or left eye [Figure 4]. We insisted on the details of his past medical history and recent history of medication or exposition, and he finally revealed inhalation of "*poppers*" for the first time a day before the beginning of the symptoms. He had not used any other drugs or alcohol during this event.

DISCUSSION

Popper is an old drug; however, it is relatively new to

Access this article online	
Quick Response Code:	Website: www.thepajo.org
	DOI: 10.4103/PAJO.PAJO_18_19

This is an open access journal, and articles are distributed under the terms of the Creative Commons Attribution-NonCommercial-ShareAlike 4.0 License, which allows others to remix, tweak, and build upon the work non-commercially, as long as appropriate credit is given and the new creations are licensed under the identical terms.

For reprints contact: reprints@medknow.com

How to cite this article: Flores RC, Rueda JR. Poppers' maculopathy. Pan Am J Ophthalmol 2019;1:8.

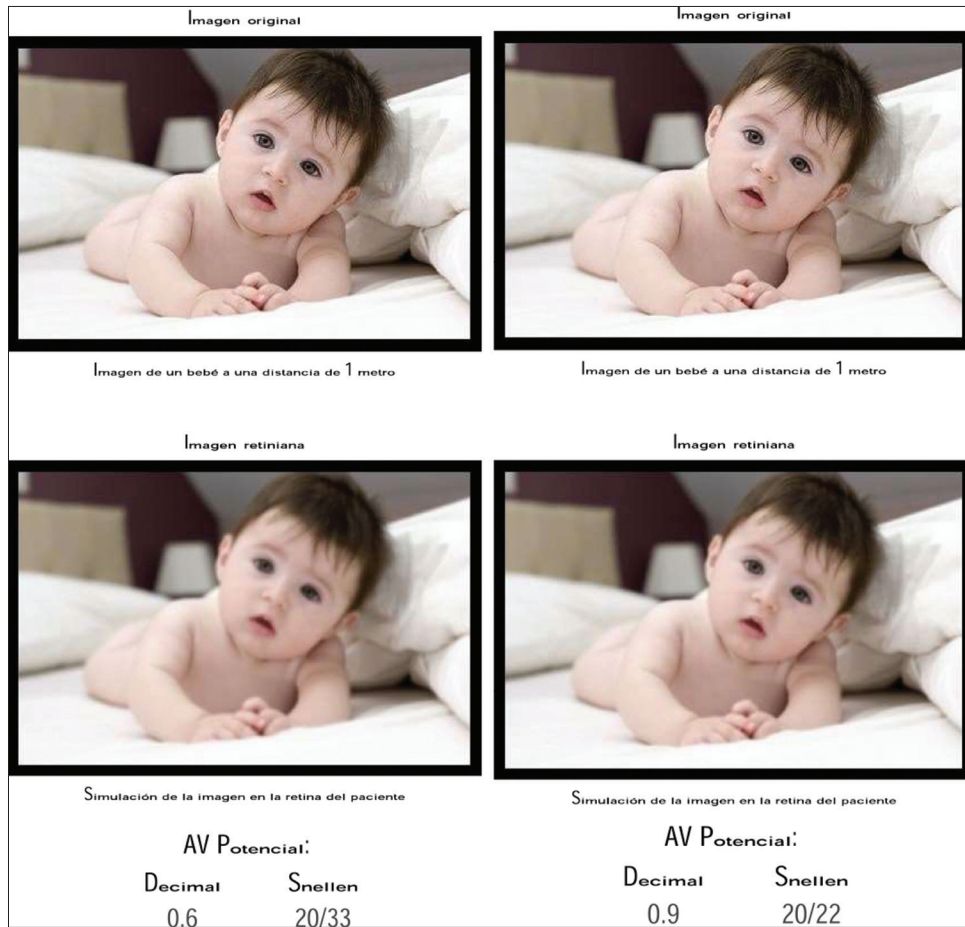


Figure 1: High Resolution (HR) shows the normal picture obtained in a healthy patient on the right (left side) and left (right side) eyes on the upper two images. In the inferior picture, there is a simulation of how the patient is perceiving his actual image distortion, showing a decrease in visual quality in both eyes

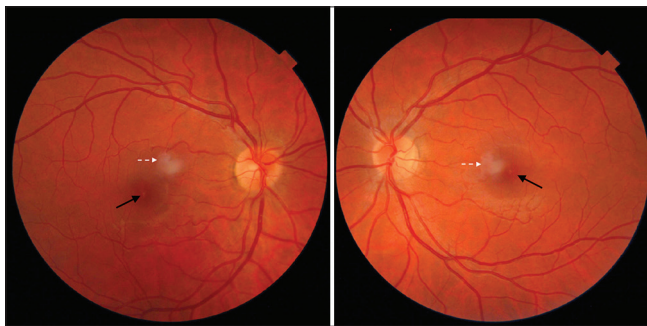


Figure 2: Mild retinal pigmented epithelium (RPE) macular changes in both eyes (black arrow). White arrow points to an image artifact

South America; now, its usage is increasing in young people at parties as a recreational and apparently harmless substance. Few studies have described a small but yet significant proportion of poppers users that complain of visual symptoms, even after first use.^[1-4] Symptoms described are blurred vision on central visual field; scotoma and phosphenes that can persist for hours and even days; and subtle foveal changes such as yellow deposits on fundus evaluation.^[2,3]

On funduscopy, the presence of bilateral yellow dots at the fovea may indicate correlation with the findings on OCT.^[5] Reports have shown a macular disruption in the EZ (hyper- or hyporeflectivity) visualized on OCT that can vary among patients and that can persist or resolve after abstinence of the drug and that are independent of the time of exposition,^[2,5,6] suggesting the involvement of the outer retina instead of retinal pigment epithelium or retinal circulation.

A retrospective study at Moorfields Eye Hospital found three distinct phenotypes of maculopathy associated to poppers. The first, a subfoveal disturbance of the EZ, was the most common type, with a “fuzzy” aspect of EZ on OCT; followed by the vitelliform-like lesion type, with a more diffuse foveal involvement that tends to occur among chronic users and does not improve over time despite drug cessation; and finally, the microhole type, an asymmetric well-defined subfoveal defect of the ellipsoid layer.^[7]

The exact pathophysiological mechanism remains unknown, but different theories have been proposed.

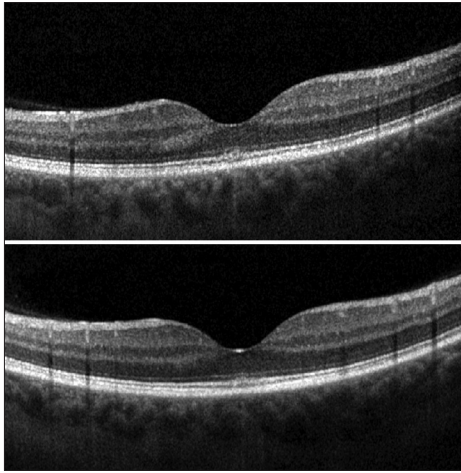


Figure 3: Spectral domain-optical coherence tomography shows a mild foveal disruption on the right (upper) and left (lower) eyes in ellipsoid zone and inner limiting membrane

One of them suggests that poppers can induce overregulation of the enzyme nitric oxide synthase and then an overproduction of nitric oxide which causes macular toxicity, especially on photoreceptors.^[2,3] The overproduction of zeaxanthin has also been described as a possible causative mechanism due to an increase in light toxicity, as well as direct damage in retinal perfusion.^[2,3] Another theory points to the activation of the enzyme guanylate cyclase that can maximize cone and decrease rod responses to light and be responsible for the phosphenes reported by patients.^[2,3] However, there is not enough information that support any of these theories.

There is no treatment reported, and symptoms can resolve in almost 32%–70% of cases after cessation.^[1,6,7]

CONCLUSION

Poppers' usage is increasing among young people with the possibility of visual alterations such as phosphenes and blurred vision that can persist over time, as a result of macular toxicity and disruption of outer retinal layers on OCT.

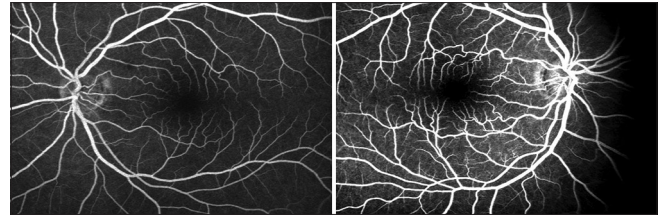


Figure 4: Fluorescein angiography shows no abnormalities on the left or right eye

Declaration of patient consent

The authors certify that they have obtained all appropriate patient consent forms. In the form the patient(s) has/have given his/her/their consent for his/her/their images and other clinical information to be reported in the journal. The patients understand that their names and initials will not be published and due efforts will be made to conceal their identity, but anonymity cannot be guaranteed.

Financial support and sponsorship

Nil.

Conflicts of interest

There are no conflicts of interest.

REFERENCES

1. Davies AJ, Borschmann R, Kelly SP, Ramsey J, Ferris J, Winstock AR. The prevalence of visual symptoms in poppers users: A global survey. *BMJ Open Ophthalmol* 2017;1:e000015.
2. Rewbury R, Hughes E, Purbrick R, Prior S, Baron M. Poppers: Legal highs with questionable contents? A case series of poppers maculopathy. *Br J Ophthalmol* 2017;101:1530-4.
3. Docherty G, Eslami M, O'Donnell H. "Poppers maculopathy": A case report and literature review. *Can J Ophthalmol* 2018;53:e154-6.
4. Gruener AM, Jeffries MA, El Housseini Z, Whitefield L. Poppers maculopathy. *Lancet* 2014;384:1606.
5. Hui M, Galvin J, Chilov M, Gabrielle PH, Fung AT. Popper maculopathy: Long term follow-up and case series. *Retin Cases Brief Rep*. 2017 Nov 10. doi: 10.1097/ICB.0000000000000650. [Epub ahead of print].
6. Pahlitzsch M, Mai C, Jousseaume AM, Bergholz R. Poppers maculopathy: Complete restitution of macular changes in OCT after drug abstinence. *Semin Ophthalmol* 2016;31:479-84.
7. Van Bol LB, Kurt RA, Keane PA, Pal B, Sivaprasad S. Clinical phenotypes of poppers maculopathy and their links to visual and anatomic recovery. *Ophthalmology* 2017;124:1425-7.