

## CASE REPORT

# Laser in situ keratomileusis flap interface fluid syndrome after Descemet membrane endothelial keratoplasty



Luis Izquierdo Jr, MD, MSc, PhD, Jose F. Lopez, MD, Maria A. Henriquez, MD, MSc, PhD

We report 2 cases of patients with a history of laser in situ keratomileusis (LASIK) surgery. Endothelial damage resulted from complicated phacoemulsification in 1 patient and from iris-fixated phakic intraocular lens implantation in the other patient. Descemet membrane endothelial keratoplasty (DMEK) was performed to correct the damaged endothelium. After uneventful surgery, both patients presented with liquid interface beneath the LASIK flap, which was

evident on anterior segment optical coherence tomography (OCT). In both cases, the LASIK flap was lifted, the liquid removed, and the flap placed correctly. Significant improvement in the corneal appearance and the corrected distance visual acuity was seen. Anterior segment-OCT showed resolution of the flap interface.

JCRS Online Case Reports 2017; 5:21–23 © 2016 ASCRS and ESCRS.

Descemet membrane endothelial keratoplasty (DMEK) has become an alternative treatment for endothelial disease.<sup>1</sup> Although it requires a long learning curve, when performed adequately, DMEK is safe and predictable and offers early visual rehabilitation.<sup>2,3</sup> The procedure has been associated with a low rate of immunogenic rejection.<sup>4</sup> Complications related to DMEK include graft detachment, primary graft failure, pupillary block, and chronic elevated intraocular pressure (IOP).<sup>5</sup>

As a result of the growing popularity of laser in situ keratomileusis (LASIK), endothelial dysfunction will be more common after cataract surgery in patients who have had LASIK. We describe 2 post-LASIK patients who developed a liquid interface after uneventful DMEK surgery performed with the standard “scuba” technique described by Guerra et al.<sup>6</sup>

## CASE REPORTS

### Case 1

A 45-year-old man was referred to our center for management of endothelial dysfunction that developed 60 days after phacoemulsification surgery. Uneventful LASIK had been performed 10 years earlier in Peru. (A microkeratome had probably been used for the surgery as it was the only option at that time.) At the time of referral, the uncorrected distance visual acuity (UDVA) was 20/800 and the corrected distance visual acuity (CDVA), 20/400; 3+ corneal edema and Descemet membrane folds were observed (Figure 1, A). The IOP was 14 mm Hg, and B-scan ultrasound (US) showed a normal posterior pole.

Uneventful DMEK was performed to correct the endothelial dysfunction. The endothelial cell count (ECC) of the donor was

2810 cells/mm<sup>2</sup> (measured by specular microscopy), and the tissue was in good condition. The DMEK graft diameter was 8.25 mm, and the diameter of Descemet stripping in the recipient was 8.75 mm. No additional manipulation was required to place the donor tissue, and the tissue was inserted only once.

On the first day after the DMEK procedure, the CDVA was 20/100; 2+ corneal edema and folds were seen at the slitlamp examination. Anterior segment optical coherence tomography (AS-OCT) was performed to verify the graft position and showed a liquid interface beneath the LASIK flap at a depth of 170 μm (in the center) and central corneal thickness (CCT) of 1006 μm with a fully attached graft (Figure 1, B)

The follow-up examinations at 2 days and 4 days showed the interface decreased slightly from 170 μm to 110 μm at the center and the CCT decreased from 1006 μm to 742 μm (Figure 1, C). The examinations at 6 days and 8 days showed no change in the liquid interface from that seen at 4 days; the corneal edema and folds persisted, and no improvement in CDVA was seen even though the endothelial graft was well placed.

At 8 days, the 10-year-old LASIK flap was lifted, the liquid was removed, and the flap was dried and repositioned. One day after the procedure, a clear cornea was observed at the slitlamp examination, the CCT decreased to 544 μm, the CDVA improved from 20/100 to 20/30, and AS-OCT showed that the interface had disappeared with no measurable space; however, there was a small superior partial graft detachment (Figure 1, C). The latest examination at 1 month showed a clear cornea (Figure 1, D) and no partial detachment.

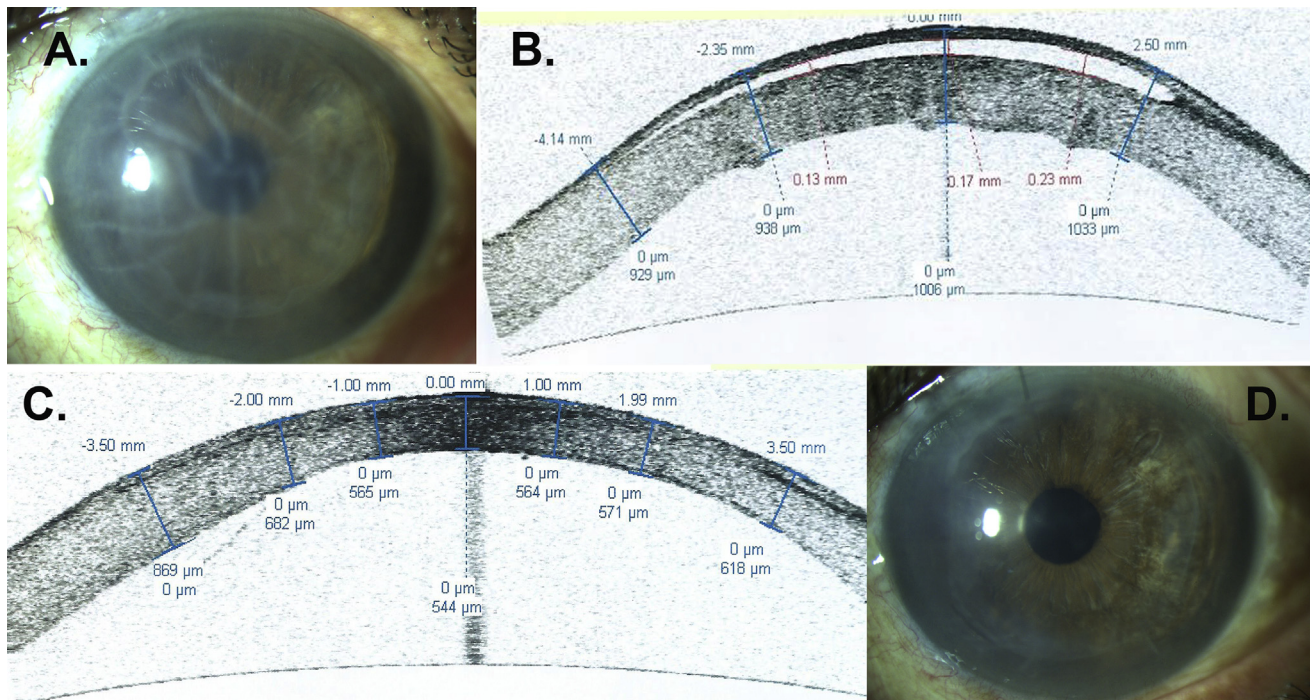
### Case 2

A 39-year-old man with a history of phakic intraocular lens implantation 12 years earlier was referred to our center for management of corneal decompensation. Uneventful LASIK had been performed in

Submitted: May 19, 2016 | Final revision submitted: August 30, 2016 | Accepted: August 31, 2016

From the Research Department, Oftalmo Salud, Instituto de Ojos, Lima, Peru.

Corresponding author: Maria A. Henriquez, MD, MSc, PhD, Instituto de Ojos, Oftalmo Salud, Avenida Javier Prado Este 1142, San Isidro, Lima 27, Peru. E-mail: [mariale\\_1610@hotmail.com](mailto:mariale_1610@hotmail.com).



**Figure 1.** A: Corneal edema and Descemet membrane crease. B: Anterior segment OCT 24 hours after DMEK showing fluid interface of 170  $\mu\text{m}$  and CCT of 1006  $\mu\text{m}$ . C: Anterior segment OCT 24 hours after lifting and repositioning the flap; CCT of 544  $\mu\text{m}$ . D: Clear central cornea 24 hours after repositioning the flap.

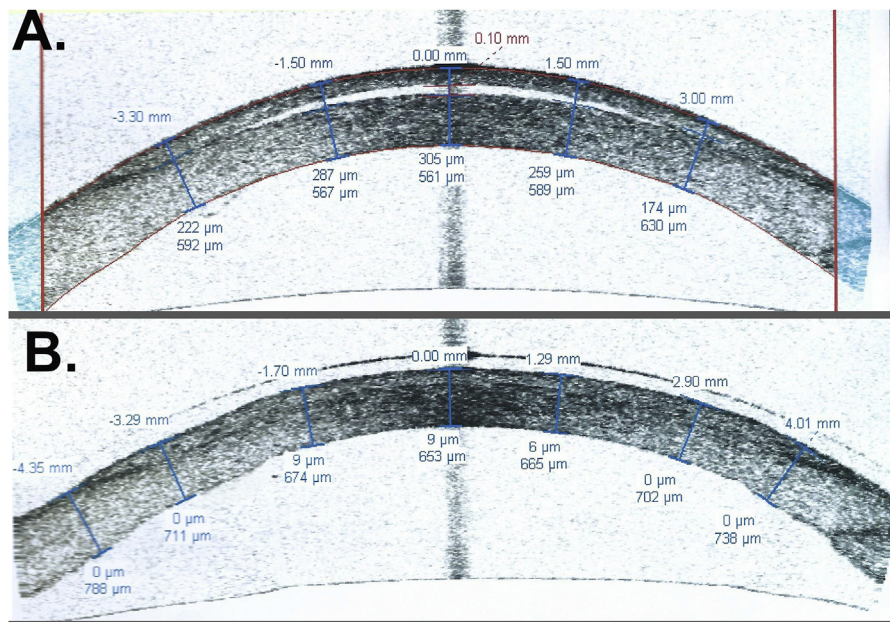
Peru 12 years earlier. (A microkeratome had probably been used for the surgery as it was the only option at that time.) At the time of referral, the UDVA was 20/1200 and the CDVA, 20/800; 3+ corneal edema and Descemet membrane folds were evident. The IOP was 14 mm Hg, and the B-scan US showed a normal posterior pole.

Uneventful DMEK was performed by the surgeon in the first case. The ECC of the donor was 3025 cells/ $\text{mm}^2$  (measured by specular microscopy), and the tissue was in good condition. The DMEK graft diameter was 8.25 mm, and the diameter of Descemet stripping in the recipient was 8.75 mm. No extra manipulation was needed to adequately place the donor tissue, and the tissue was inserted only once.

Twenty-four hours after DMEK, slitlamp examination showed persistent corneal edema and folds. Corneal AS-OCT showed

adequate positioning of the endothelial graft but liquid interface with a central diameter of 100  $\mu\text{m}$  (in the center) and CCT of 866  $\mu\text{m}$  (Figure 2, A); a small partial detachment was seen at the periphery on the left side of the image, suggestive of a small partial graft detachment, which could not be confirmed by slitlamp examination. Forty-eight hours after DMEK, the interface decreased slightly from 100  $\mu\text{m}$  to 70  $\mu\text{m}$  at the center and the CCT decreased from 866  $\mu\text{m}$  to 841  $\mu\text{m}$ .

Seventy-two hours after DMEK, the LASIK flap was lifted, the liquid interface removed, and the flap repositioned. One day after the procedure, the CDVA improved from 20/800 to 20/40, a clear cornea was observed; AS-OCT showed no liquid interface, a decrease in CCT to 662  $\mu\text{m}$  (Figure 2, B), and full graft attachment. As the next AS-OCT showed no evidence of partial detachment, a



**Figure 2.** A: Anterior segment OCT 24 hours after DMEK showing fluid interface of 100  $\mu\text{m}$  and CCT of 866  $\mu\text{m}$ . B: Anterior segment OCT 24 hours after lifting and repositioning the flap; CCT of 653  $\mu\text{m}$ .

spontaneous resolution was assumed. No further intervention was needed.

## DISCUSSION

Complications related to the DMEK procedure include graft detachment, primary graft failure, pupillary block, and chronic elevated IOP.<sup>7</sup> Those related to the LASIK flap interface include epithelial ingrowth, infections, flap folds, flap displacement, diffuse lamellar keratitis, bacterial keratitis, dry eye, ectasia, and interface fluid syndrome.<sup>8,9</sup> The LASIK flap interface fluid syndrome was first described by Lyle and Jin<sup>9</sup> and associated with steroid-induced ocular hypertension. To our knowledge, complications in the flap interface after a DMEK procedure have not been reported.

During DMEK, there is mechanical removal of the Descemet membrane and endothelium, which has a dysfunctional ion transport system. After the donor graft is placed, endothelial function and regulation of the water content of the corneal stroma are reestablished.<sup>10</sup> Because there are no reports of a fluid-flap interface after cataract or other surgery in post-LASIK patients, we believe that the manipulation of the endothelium and/or the high pressure induced by the air bubble during DMEK plays a role in creating the flap interface in the immediate postoperative period in patients with a history of LASIK surgery. During the surgery or the reestablishment of endothelial function, this liquid might accumulate beneath the flap and create the interface. Reports of lifting the flap long after the primary surgery<sup>11</sup> suggest that LASIK flaps never completely heal and the virtual space could be filled after an alteration in the ion transport system or changes in pressure inside the anterior chamber that occurred in the DMEK procedure.<sup>12</sup>

In the future, DMEK candidates with a history of LASIK will be more common, and therefore we must be aware of a possible liquid interface complication. In both cases presented, drainage of the liquid interface was required because corneal recovery was not achieved with conservative follow-up. Drainage resulted in a quick reduction in corneal pachymetry and improvement in visual acuity and corneal edema during the first 24 hours and continuing up to 1 month. We recommend performing AS-OCT to monitor the endothelial attachment and the flap interface in DMEK patients who have a history of LASIK.

## REFERENCES

1. Anshu A, Price MO, Tan DTH, Price FW Jr. Endothelial keratoplasty: a revolution in evolution. *Surv Ophthalmol* 2012; 57:236–252
2. Price MO, Giebel AW, Fairchild KM, Price FW Jr. Descemet's membrane endothelial keratoplasty; prospective multicenter study of visual and refractive outcomes and endothelial survival. *Ophthalmology* 2009; 116:2361–2368
3. Price MO, Price FW Jr. Descemet's membrane endothelial keratoplasty surgery: update on the evidence and hurdles to acceptance. *Curr Opin Ophthalmol* 2013; 24:329–335
4. Hlinomazová Z, Horácková M, Pirnerová L. [DMEK (Descemet membrane endothelial keratoplasty)—early and late postoperative complications] [Czechoslovakian]. *Cesk Slov Oftalmol* 2011; 67:75–79
5. Suh LH, Yoo SH, Deobhakta A, Donaldson KE, Alfonso EC, Culbertson WW, O'Brien TP. Complications of Descemet's stripping with automated endothelial keratoplasty; survey of 118 eyes at one Institute. *Ophthalmology* 2008; 115:1517–1524
6. Guerra FP, Anshu A, Price MO, Giebel AW, Price FW. Descemet's membrane endothelial keratoplasty; prospective study of 1-year visual outcomes, graft survival, and endothelial cell loss. *Ophthalmology* 2011; 118:2368–2373
7. Regueiro-Salas R, Orduña-Domingo E, Sastre-Comas M. Descemet's membrane endothelial keratoplasty (DMEK): outcomes after three years of experience. *J Emmetropia* 2014; 5:191–199. Available at: <http://www.journalofemmetropia.org/numeros/pdf/5-4/Journal-article-3.pdf>. Accessed September 13, 2016
8. Mulhern MG, Condon PI, O'Keefe M. Myopic and hyperopic laser in situ keratomileusis retreatments; indications, techniques, limitations, and results. *J Cataract Refract Surg* 2001; 27:1278–1287
9. Lyle WA, Jin GJC. Interface fluid associated with diffuse lamellar keratitis and epithelial ingrowth after laser in situ keratomileusis. *J Cataract Refract Surg* 1999; 25:1009–1012
10. Kanski JJ, Bowling B. *Kanski's Clinical Ophthalmology; A Systematic Approach*, 7th ed. Edinburgh, Scotland, Elsevier, 2011; 249
11. Al Reefy M, Ayachit S. Re-lifting the LASIK flap 16 years after primary surgery. *Bahrain Med Bull* 2014; 36:103–104. Available at: [http://www.bahrainmedicalbulletin.com/june\\_2014/Re-lifting-LASIK.pdf](http://www.bahrainmedicalbulletin.com/june_2014/Re-lifting-LASIK.pdf). Accessed September 13, 2016
12. McKee Y, Price F, Feng M, Tenkman L, Burkhart Z. *The Digital Manual of Ophthalmic Surgery and Theory. DMEK: Tissue Preparation, Surgical Technique and Postoperative Care*. Interactive Medical Publishers 2014; 1; issue 1, version 1.5

**Disclosure:** None of the authors has a financial or proprietary interest in any material or method mentioned.



### First author:

Luis Izquierdo Jr, MD, MSc, PhD

Research Department, Oftalmo Salud, Instituto de Ojos, Lima, Peru