

Anterior Stromal Puncture in the Treatment of Bullous Keratopathy

Six-month Follow-up

José Alvaro P. Gomes, M.D., Daniel K.M. Haraguchi, M.D.,
Delbis U. Zambrano, M.D., Luis Izquierdo, Jr., M.D.,
Marcelo C. Cunha, M.D., and Denise de Freitas, M.D.

Purpose. This study was designed to evaluate the effect of anterior stromal puncture to treat patients with symptomatic bullous keratopathy. **Methods.** Fourteen patients with bullous keratopathy who had decreased vision and were or were not awaiting penetrating keratoplasty were evaluated before and 1, 4, 12, and 24 weeks after anterior stromal punctures with a 25-gauge needle. The patients were questioned about pain intensity, foreign-body sensation, and photophobia. Biomicroscopy, esthesiometry, and pachymetry results were evaluated. The results before and after the punctures were compared using the McNemar test, Friedman test, and multiple comparison tests. **Results.** The comparisons among before and 1, 4, and 12 weeks after the anterior stromal puncture of pain ($p = 0.00000556$), photophobia ($p = 0.0252$), foreign-body sensation ($p = 0.0000743$), and esthesiometry ($p = 0.0243$) showed significant statistical differences in terms of decreasing symptoms and corneal sensitivity. The average pachymetry did not show statistical difference among before and 1, 4, 12, and 24 weeks after the procedure ($p = 0.956$). We did not find important differences in terms of corneal neovascularization. **Conclusion.** Anterior stromal puncture is an effective, simple, and low-cost alternative for treating patients with symptomatic bullous keratopathy.

Key Words: Bullous keratopathy—Anterior stromal puncture—Corneal edema.

Bullous keratopathy is a corneal disease caused by endothelial decompensation secondary to trauma, glaucoma, or congenital abnormalities.¹ The results are corneal edema and epithelial or subepithelial bullae formation, leading to decreased vision, pain, photophobia, and epiphora.^{1,2} Several therapies are available to treat this condition: bandage contact lenses, conjunctival flap, electrocauterization, topical therapy with antiglaucoma medication, 5% saline or nonsteroidal antiinflammatory agents.^{1–3} A good outcome, however, is not always achieved, and treatment can be frustrating.

Anterior stromal puncture (ASP) has been successfully used to treat recurrent erosion, particularly when lesions are not located in

the visual axis.^{4–8} ASP seems to promote the secretion of extracellular matrix proteins, which form new adhesion complexes between the epithelium and the underlying stroma.^{4–9} Cormier et al.² reported good results at 3-month follow-up of ASP for patients with symptomatic bullous keratopathy.

In our practice, we often see patients with bullous keratopathy who present with severe discomfort; many of them are candidates for penetrating keratoplasty (PK). However, the number of corneas available for transplant does not always fulfill the need, making their painful wait longer. The purpose of this study was to determine the therapeutic effects of ASP in patients with symptomatic bullous keratopathy.

MATERIALS AND METHODS

A prospective study was carried out at the External Disease and Cornea Service, Department of Ophthalmology, Federal University of São Paulo (UNIFESP), São Paulo, Brazil. We studied 14 patients presenting with symptomatic bullous keratopathy and decreased vision, who either were awaiting PK or were not candidates for the procedure. Exclusion criteria were the presence of intercurrent epithelial disease, inadequate compliance with follow-up, or refusal to participate in the study.

The patients were seen before ASP and 1, 4, 12, and 24 weeks after the procedure. The evaluation involved a questionnaire with several items, such as foreign-body sensation (on a scale of 0 to 3+), pain intensity (0 to 3+), photophobia (0 to 3+), and insomnia related to pain. The complete ophthalmologic examination included a careful slit-lamp examination with or without fluorescein to detect Descemet folds, vascularization, subepithelial bullae, and epithelial defects; detailed drawings of the cornea; slit-lamp photographs; ultrasonic pachymetry (Humphrey Instruments Inc., San Leandro, CA, U.S.A.) performed in the center of the cornea and in eight points 3.5 mm from it; corneal sensitivity (Cochet-Bonnet Esthesiometer; Lunneau, Paris, France); and intraocular pressure (Goldmann tonometer).

ASP was performed by the same ophthalmologist (J.A.P.G.), as follows: one drop of proparacaine 0.5% was instilled in the eye. Under slit-lamp magnification, multiple (approximately 100) closely placed nonconfluent punctures were performed in the anterior stroma of each corneal quarter using a 25-gauge sterile needle. Punctures were applied through loose edematous epithel-

Submitted September 8, 2000. Revision received February 28, 2001. Accepted March 20, 2001.

From the External Disease and Cornea Service, Department of Ophthalmology, Federal University of São Paulo (UNIFESP), Brazil.

Address correspondence and reprint requests to Dr. J.A.P. Gomes, R. Sarbrá, 566 cjuto. 212, São Paulo SP-01239-010, Brazil. E-mail: jagomes@uol.com.br

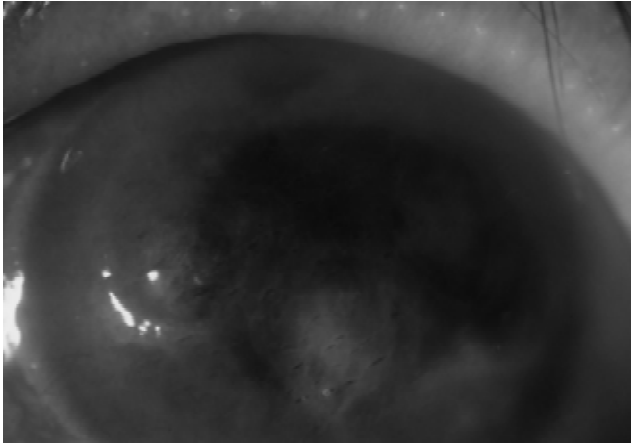


FIG. 1. Biomicroscopic view of a cornea with bullous keratopathy immediately after anterior stromal puncture (original magnification, $\times 25$).

lium without debridement (Fig. 1). After ASP, a bandage contact lens was placed, which was removed 7 days later. In the posttreatment period, patients were instructed to use one drop of ofloxacin 3 mg/mL (Ocuflox, Allergan, Irvine, CA, U.S.A.) four times daily for 7 days and one drop of sodium diclofenac 1 mg/mL (Still; Allergan, Guarulhos, Brazil) four times daily for 5 days.

The McNemar test was used to analyze the concordance between pretreatment and final evaluation (24 weeks). Differences in the continuous (pachymetry and esthesiometry) and subjective (pain, photophobia, and foreign-body sensation) variables at each visit (before treatment and 1, 4, 12, and 24 weeks) were analyzed using the Friedman test. If the Friedman test detected a significant difference, multiple comparisons were performed between the different follow-up evaluations. The significance level was considered to be $p < 0.05$ (5%).

RESULTS

The results from 14 patients who underwent anterior stromal punctures with 6 months of follow-up were analyzed. Eight patients (57.14%) were women and six (42.86%) were men. The

TABLE 1. Comparisons of pain, photophobia, and foreign body sensation evaluations

Comparisons	Pain	Photophobia	Foreign body sensation
0 vs. 1 vs. 4 vs. 12	$\chi^2 = 29.73^*$	$\chi^2 = 11.13^*$	$\chi^2 = 24.16^*$
0 vs. 1	NS	NS	*
0 vs. 4	*	NS	*
0 vs. 12	*	NS	*
0 vs. 24	*	*	*
1 vs. 4	NS	NS	NS
1 vs. 12	NS	NS	NS
1 vs. 24	NS	NS	NS
4 vs. 12	NS	NS	NS
4 vs. 24	NS	NS	NS
12 vs. 24	NS	NS	NS

* $p < 0.05$.

0 vs. 1 vs. 4 vs. 12 vs. 24 = Friedman test results; 0 vs. 1, 0 vs. 4, 0 vs. 12, 0 vs. 24, 1 vs. 4, 1 vs. 12, 1 vs. 24, 4 vs. 12, 4 vs. 24, 12 vs. 24 = multiple comparisons results.

0 indicates before; 1, 1 week; 4, 4 weeks; 12, 12 weeks; 24, 24 weeks; NS, not significant ($p > 0.05$).

TABLE 2. Descriptive results of esthesiometry (g/mm^2) before and 1, 4, 12, and 24 weeks after the procedure

Patient	Before	1 wk	4 wk	12 wk	24 wk
1	12.84	8.84	12.84	17.68	6.64
2	0.96	0.96	1.16	1.84	4.6
3	1.40	2.40	17.68	17.68	17.68
4	2.40	4.60	0.96	2.40	4.60
5	12.84	17.68	17.68	17.68	17.68
6	4.60	6.64	8.84	8.84	8.84
7	6.64	6.64	6.64	3.20	6.64
8	4.60	4.60	12.84	6.64	6.64
9	3.20	12.84	6.64	6.64	6.64
10	3.20	6.64	8.84	8.84	6.64
11	0.96	6.64	8.84	8.84	8.84
12	17.68	17.68	17.68	17.68	17.68
13	1.40	12.84	12.84	8.84	12.84
14	12.84	12.84	4.6	17.68	12.84
Mean	6.11	8.70	9.86	10.32	9.91
Median	3.90	6.64	8.84	8.84	7.74

mean age was 60 years (range, 36–85 years). At initial diagnosis, there were 10 patients with pseudophakic bullous keratopathy (71.43%), three with endothelial decompensation caused by corneal graft failure (21.43%), and one with aphakic bullous keratopathy (7.14%).

All procedures were performed successfully. The mean duration of the procedure was 4 minutes. Four patients (28.57%) needed more than one session to produce significant improvement of symptoms. We did not observe any postoperative complications such as persistent epithelial defect, inflammation, or infection.

All 14 patients reported reduced pain after the procedure. Moreover, nine of them (64.29%) reported absence of pain at the 6-month follow-up visit ($p = 0.0736$). The patients had a statistically significant decrease in pain between pretreatment and 1, 4, 12, and 24 weeks ($p = 0.0000556$). Multiple comparisons showed significant differences between pretreatment and 4, 12, and 24 weeks (Table 1). As to photophobia, the difference between pretreatment and 1-, 4-, 12-, and 24-week evaluations was statistically significant ($p = 0.0252$), but multiple comparison showed a significant difference only between pretreatment and final evaluation (24 weeks) (Table 1). Almost every patient showed a decrease in foreign-body sensation. The difference between pretreatment and 1-, 4-, 12-, and 24-week evaluations was statistically

TABLE 3. Comparisons of esthesiometry and pachymetry results

Comparisons	Esthesiometry	Average pachymetry
0 vs. 1 vs. 4 vs. 12	$\chi^2 = 11.21^*$	$\chi^2 = 0.67$ (NS)
0 vs. 1	NS	—
0 vs. 4	NS	—
0 vs. 12	*	—
0 vs. 24	*	—
1 vs. 4	NS	—
1 vs. 12	NS	—
1 vs. 24	NS	—
4 vs. 12	NS	—
4 vs. 24	NS	—
4 vs. 24	NS	—
12 vs. 24	NS	—

* $p < 0.05$.

0 vs. 1 vs. 4 vs. 12 vs. 24 = Friedman test results; 0 vs. 1, 0 vs. 4, 0 vs. 12, 0 vs. 24, 1 vs. 4, 1 vs. 12, 1 vs. 24, 4 vs. 12, 4 vs. 24, 12 vs. 24 = multiple comparisons results.

NS indicates not significant ($p > 0.05$); 0, before; 1, 1 week; 4, 4 weeks; 12, 12 weeks; 24, 24 weeks.

TABLE 4. Descriptive results of average pachymetry (μm) before and 1, 4, 12, and 24 weeks after the procedure

Patient	Before	1 wk	4 wk	12 wk	24 wk
1	762	797	863	885	845
2	745	747	741	748	752
3	801	750	746	808	769
4	837	802	812	676	751
5	1,029	1,021	1,009	1,025	1,018
6	916	882	885	772	830
7	757	763	765	691	754
8	972	1,003	1,003	959	972
9	902	939	906	923	931
10	799	790	797	813	803
11	873	856	873	851	909
12	912	802	846	874	846
13	672	715	782	724	776
14	979	905	805	916	958
Mean	854	841	845	833	851
Median	855	802	829	832	837

significant ($p = 0.0000743$). Multiple comparisons showed significant differences between pretreatment and all posttreatment evaluations (Table 1). All four patients who presented with insomnia caused by ocular symptoms before the procedure reported its absence after 6 months, but the difference was not statistically significant ($p = 0.2673$).

Statistically significant differences in esthesiometry were found between pretreatment and 1-, 4-, 12-, and 24-week evaluations ($p = 0.0243$). According to multiple comparisons, only the differences between initial and 12 weeks and initial and 24 weeks were statistically significant (Tables 2 and 3).

Average pachymetry measurements did not alter significantly ($p = 0.956$) (Tables 3 and 4). From the 14 patients, only 2 (14.29%) had increased vascularization, and in both cases, it was only superficial. We observed a decrease in epithelial and subepithelial bullae and an increase in subepithelial fibrosis with a decrease in corneal transparency in all patients.

DISCUSSION

Patients with bullous keratopathy present very often with symptoms that interfere with their quality of life. Several treatments have been described to reduce their pain and discomfort. A bandage contact lens is a simple and effective option, but it can increase vascularization and the risk of infection.³ Steroids and hyperosmotic agents have showed limited results, particularly in the more severe cases.^{1,2} Bowman's layer cauterization is effective for advanced cases.^{1,2} However, it requires a cautery and an operating room. Moreover, it may induce severe alterations in corneal shape, vascularization, and even stromal necrosis that may reduce the chance of a successful PK in the future.^{1,2}

ASP is a simple, low-cost option that requires only a slit-lamp and needle.⁴⁻⁸ In this study, we found that the procedure is very easy to perform. All patients tolerated the 400 punctures well, which were performed in less than 5 minutes. The choice of the 25-gauge needle follows the recommendation of Katsev et al.¹⁰ These authors found that it is the best needle to penetrate two thirds of the anterior stroma safely and causes less damage to adjacent tissue. The needle may also be bent to increase safety.

Cormier et al.² reported good results with this procedure in the treatment of bullous keratopathy. Our results confirm theirs regarding relief of symptoms, particularly pain. All patients reported relief of pain, and 65% reported absence of pain. Photophobia and foreign-body sensation were also considerably reduced. Like Cormier et al.,² we also observed significant increase in esthesiometry values, showing decreased sensibility 4 weeks after the procedure. Unlike them, we observed no increase in corneal thickness. Differences in the puncture technique or pachymetry may account for the difference.

The mechanism(s) to explain how the stromal punctures reduce symptoms is not clear yet. The pain is related to bullae rupture, possibly because of nerve exposure in the cornea. It is possible that ASP induces scarring and fibrosis, which might produce a barrier to bullae formation. The theory that epithelial plugs would grow into the punctured stroma was not fully proved. Recently, Hsu et al.⁹ showed by using immunohistochemical techniques an increase in expression of extracellular matrix proteins, which are important in basal epithelial cell adhesion (fibronectin, laminin, type IV collagen) in punctured corneas. The secretion of these basal membrane components would increase epithelial adhesion to the subjacent stroma. Increased epithelial adhesion, together with subepithelial fibrosis, would create a barrier to prevent liquid from penetrating into the subepithelial space and prevent the development of bullae.⁹

We noticed that the bullae decreased or disappeared in the punctured area. Some days later, subepithelial fibrosis was observed. The increase in vascularization was mild and superficial, which is an advantage when compared with other more aggressive treatments.

In summary, ASP reduces symptoms, particularly pain, in patients with bullous keratopathy. It is easy to perform, inexpensive, and effective and should be considered as an option in the treatment of these patients.

REFERENCES

1. Aquavella JV. Corneal edema. In: Leibowitz HM, ed. *Corneal disorders: clinical diagnoses and management*. Philadelphia: WB Saunders, 1984:164-82.
2. Cormier G, Brunette I, Boisjoly HM, et al. Anterior stromal punctures for bullous keratopathy. *Arch Ophthalmol* 1996;114:654-8.
3. Plotnik RD, Mannis MJ, Schwab IR. Therapeutic contact lens. *Int Ophthalmol Clin* 1991;31:35-52.
4. Rubinfeld RS, Laibson PR, Cohen EC, et al. Anterior stromal punctures for recurrent erosion: further experience and new instrument. *Ophthalmic Surg* 1990;21:318-26.
5. McLean EN, McRae SM, Rich LF. Recurrent erosion treatment by anterior stromal puncture. *Ophthalmology* 1986;93:784-8.
6. Wood TO. Recurrent erosion. Presented at the 14th Annual Meeting of the Castroviejo Cornea Society, Las Vegas, November 1988.
7. Kenyon KR. Recurrent corneal erosion: pathogenesis and therapy. *Int Ophthalmol Clin* 1979;19:169-95.
8. Galbavy EJ, Mobilia EF, Kenyon KR. Recurrent corneal erosion. *Int Ophthalmol Clin* 1984;24:107-31.
9. Hsu JKW, Rubinfeld RS, Barry P, et al. Anterior stromal punctures: immunohistochemical studies in human corneas. *Arch Ophthalmol* 1993;111:1057-63.
10. Katsev DA, Kincaid MC, Fouraker BD, et al. Recurrent corneal erosion: pathology of corneal puncture. *Cornea* 1991;10:418-23.