

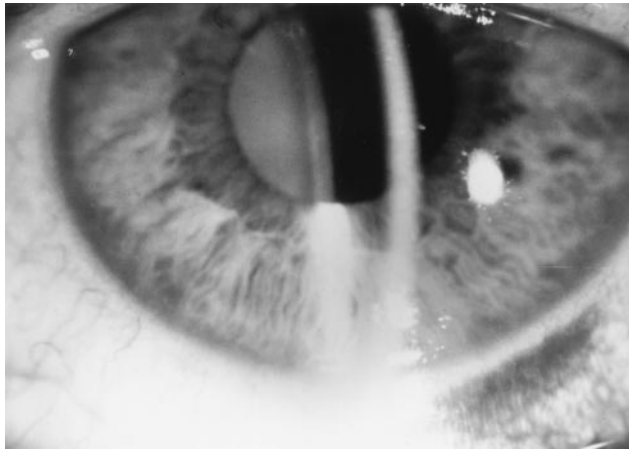FIGURE 2. The patient's left eye, with complete disappearance of corneal deposits 4 days later.

1.00% every 2 hours, ciprofloxacin 0.30% four times daily, and scopolamine 0.25% twice daily.

The patient returned 4 days later still on the above-mentioned regimen and the intrastromal corneal deposits had completely resolved (Figure 2). The remainder of the examination was unchanged, and no additional injections of 5-fluorouracil were given based on the clinical appearance of the conjunctiva.

Infectious crystalline keratopathy is usually associated with bacterial or fungal organisms and has been reported in an eye that underwent trabeculectomy with adjunctive postoperative injections of 5-fluorouracil¹ and in an eye maintained on long-term low-dose topical corticosteroids after trabeculectomy.² Noninfectious crystalline keratopathy has been reported in association with topical fluoroquinolones,³ usually in association with an epithelial defect or ulceration.⁴ In most patients, crystals of ciprofloxacin adhere to the corneal stroma in the base of an epithelial defect or ulceration and may require surgical debridement for removal. In some patients, the deposits disappear spontaneously despite continued therapy with topical ciprofloxacin. Our patient developed crystalline keratopathy associated with a subconjunctival injection of 5-fluorouracil. Although no cultures were taken from this patient, the complete resolution without any change in the postoperative antibacterial therapy and spontaneous resolution are consistent with a noninfectious process. In addition, the time in which the stromal crystals developed makes an association with the subconjunctival injection likely. Although the deposits may have been related to the use of topical ciprofloxacin, there was no associated epithelial defect or ulceration present at any time during the postoperative period.

Noninfectious crystalline keratopathy may occur as a result of postoperative injections with 5-fluorouracil. This

should be included in the differential diagnosis of crystalline keratopathy.

REFERENCES

1. Patitsas C, Rockwood EJ, Meisler DM, McMahon JT. Infectious crystalline keratopathy occurring in an eye subsequent to glaucoma filtering surgery with postoperative subconjunctival 5-fluorouracil. *Ophthalmic Surg* 1991;22:412-413.
2. Apel A, Campbell I, Rootman DS. Infectious crystalline keratopathy following trabeculectomy and low-dose topical steroids. *Cornea* 1995;14:321-323.
3. Wilhelmus KR, Hyndiuk RA, Caldwell DR, et al. 0.3% ciprofloxacin ophthalmic ointment in the treatment of bacterial keratitis: the Ciprofloxacin Ointment/Bacterial Keratitis Study Group. *Arch Ophthalmol* 1993;111:1210-1218.
4. Leibowitz HM. Clinical evaluation of ciprofloxacin 0.3% ophthalmic solution for treatment of bacterial keratitis. *Am J Ophthalmol* 1991;112(suppl):S34-S44.

Technique for Harvesting Keratolimbic Allografts From Corneoscleral Buttons

Mark J. Mannis, MD, Martin McCarthy, MD, and Luis Izquierdo, Jr, MD

PURPOSE: To report a method for obtaining thin keratolimbic lenticules from cadaveric corneoscleral buttons for corneal epithelial stem cell allografts.

Accepted for publication Feb 24, 1999.

From the Cornea and External Disease Service, Department of Ophthalmology, University of California, Davis, Sacramento, California.

Inquiries to Mark J. Mannis, MD, 4806 Y St, Ste 2400, Sacramento, CA 95817; e-mail: mjmannis@ucdavis.edu




FIGURE 1. Required instruments for harvesting keratolimbic lenticules from corneoscleral buttons include three 3/4-inch 25-gauge needles, a silicone orbital implant sizing ball, and a long, low profile blade such as a number 72 Beaver blade.

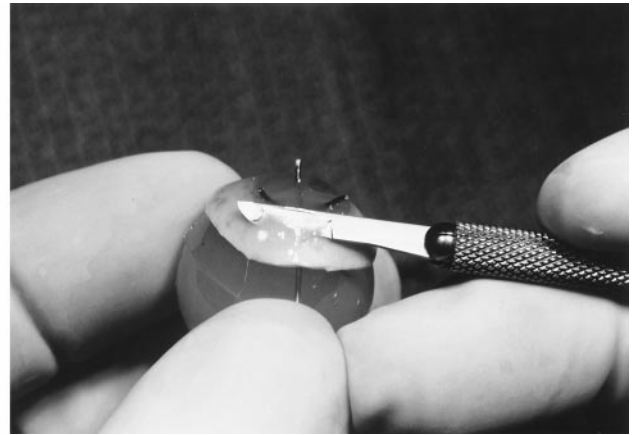



FIGURE 2. (Left) The corneoscleral button is fixed to the silicone ball with three 25-gauge needles. The hubs are then removed with heavy scissors. (Right) The orbital implant with attached corneoscleral button provides a firm, easily manipulated base to shave three or four thin, high-quality keratolimbal lenticules.

METHOD: A standard silicone orbital sizing sphere and three 25-gauge needles were employed to fix the corneoscleral button to facilitate excision of keratolimbal lenticules.

RESULT: Limbal stem cells in the form of keratolimbal lenticules were obtained without difficulty.

CONCLUSION: With this technique, thin keratolimbal lenticules of good quality can be obtained efficiently, inexpensively, and without specialized instruments. (*Am J Ophthalmol* 1999;128:237–238. © 1999 by Elsevier Science Inc. All rights reserved.)

TECHNIQUES FOR THE VISUAL REHABILITATION OF patients with ocular surface disease attributable to corneal epithelial stem cell failure are expanding and include conjunctival allografts and autografts,¹ keratolimbal allografts and autografts,¹ and human amniotic membrane transplantation.² In patients with bilateral ocular surface disease from chemical burns, aniridia³ and ocular cicatricial pemphigoid, lenticules of cadaveric limbal, corneal, and scleral tissue (keratolimbal allografts) may be used to replace depleted stem cell populations. In the United States, however, corneal tissue for transplantation is most commonly harvested and provided as a corneoscleral button rather than a whole globe,⁴ making tissue manipulation and the acquisition of lenticules difficult.

We have developed an uncomplicated technique for harvesting keratolimbal lenticules from corneoscleral buttons using supplies readily available in the operating room, including three 3/4-inch 25-gauge needles, a sterile silicone sizing sphere, a number 72 Beaver blade (Becton Dickinson, Franklin Lakes, New Jersey), and heavy scissors (Figure 1). The corneoscleral button is placed on an appropriately sized silicone orbital implant (22 mm in diameter for an adult eye) and fixed with the

25-gauge needles placed at the apices of an imaginary isosceles triangle in clear cornea (Figure 2). The needles are cut flush to the corneal surface with heavy scissors. The silicone orbital implant with attached corneoscleral button is held in the nondominant hand. Three to four thin partial-thickness keratolimbal lenticules are then easily shaved from the corneoscleral limbus with the Beaver blade. The ends of the needles can be removed from the implant with heavy forceps. This technique results in little damage to the silicone implant and does not prevent its further use. A similar technique has been employed for removing corneal tissue from corneal scleral buttons for lamellar grafts.⁵

Corneal epithelial stem cells in the form of lamellar, keratolimbal lenticules can be readily obtained from whole cadaver globes; however, eye banks usually store tissue for transplantation as a corneoscleral button. Our method of excising lamellar keratolimbal tissue from corneoscleral buttons for allograft transplantation is effective, efficient, and requires no special instruments.

REFERENCES

1. Tan DTH, Ficker LA, Buckley RJ. Limbal transplantation. *Ophthalmology* 1996;103:29–36.
2. Prabhasawat P, Tseng SCG. Impression cytology study of epithelial phenotype of ocular surface reconstructed by preserved human amniotic membrane. *Arch Ophthalmol* 1997; 115:1360–1367.
3. Nishida K, Kinoshita S, Ohashi Y, Kuwayama Y, Yamamoto S. Ocular surface abnormalities in aniridia. *Am J Ophthalmol* 1995;120:368–375.
4. 1997 Statistical Report. Eye Bank Association of America. Washington, D.C.
5. Wong DWK, Chan WK, Tan DTH. Harvesting a lamellar graft from a corneoscleral button: a new technique. *Am J Ophthalmol* 1997;123:688–689.